ORIGINAL ARTICLE

The Palatal Overlap Flap: A Modification of the Maxillary Swing Procedure to Prevent Ascending Infection

Ian T. Jackson, M.D., D.Sc. (Hon.), F.R.C.S., F.A.C.S., F.R.A.C.S. (Hon.),[1] and Daniel R. Pieper, M.D.[1]

ABSTRACT

The maxillary swing procedure provides an excellent approach to the anterior skull base region and to the clivus. The osteotomy should not be standard; it should vary with the size and position of the central skull base tumor being resected. The main reason for publishing this article is to draw attention to a method of preventing ascending infection from the oral cavity to the intracranial area using the palatal overlap flap. Examples of this approach are provided.

KEYWORDS: Weber-Fergusson incision, central skull base, clivus, osteotomy, galeal flap, palatal overlap flap

The midface approach to the skull base using a Weber-Fergusson incision has tended to be the prelude to a standard osteotomy.[1] This should not be the case; once the incision is made and the maxilla and glabellar area are reached, the remainder of the operation is planned in relation to the size and position of the tumor.[2–5] Because this approach is mainly indicated for clival tumors, the access can be relatively limited.

The value of a more limited approach is less disturbance of soft tissue and no disruption of the temporal fossa; solid and secure fixation of the maxilla is obtained at the end of the procedure.[6–8] When the latter is achieved, there is no concern about malpositioning of the occlusion, instability, and/or dental malfunction.[9,10] A modification to prevent ascending contamination and infection from the oral cavity has been devised and is presented in this article. In addition to the functional aspect, cosmesis should be satisfactory.

TECHNIQUE

The standard paranasal and central lip-splitting skin and subcutaneous tissue incision is made. Usually a small superior continuation of the incision into the glabellar area is of value for superior exposure. This portion veers medially, then can proceed vertically

[1]Craniofacial Institute, affiliated with Providence Hospital, Southfield, Michigan.

Address for correspondence and reprint requests: Ian T. Jackson, M.D., 6001 West Nine Mile Road, Third Floor Fisher Center, Southfield, MI 48075 (e-mail: ianjackson@juno.com).

Skull Base 2008;18:363–370. Copyright © 2008 by Thieme Medical Publishers, Inc., 333 Seventh Avenue, New York, NY 10001, USA. Tel: +1(212) 584-4662.

Received: February 6, 2008. Accepted: May 5, 2008. Published online: October 7, 2008.
DOI 10.1055/s-0028-1087218. ISSN 1531-5010.

as determined by a glabellar frown line, if present. The periosteum is elevated over the medial anterior face of the orbit up to the glabellar region. The periosteum on the orbital floor is also elevated. The medial aspect, which is the lateral wall of the nose, is also dissected in the subperiosteal plane as far back as is necessary. The orbital contents are now free medially and inferiorly. A horizontal osteotomy is made superiorly, as required, in the glabella and medial orbital wall. A central or lateral vertical cut is made on the nasal bones and on the medial wall of the orbit with a drill or osteotome (the former is preferred). On the inferior orbital rim laterally, an osteotomy is made vertically. The position of this osteotomy varies with the amount of exposure required (Fig. 1A). The orbital contents are dislocated laterally, keeping the periorbitum intact, and the medial and inferior cuts are joined. Using a curved osteotome, the maxilla is separated from the pterygoid plates. This requires a few strong blows and must be accomplished completely to allow ease of mobilization. On the palate, the mucoperiosteum of the nonmobilized segment is incised anteroposteriorly in such a way as to provide a significant overlapping flap when closure is accomplished (Fig. 1B). The flap has been termed the "palatal overlap flap." This is an extremely important portion of the approach. This flap is elevated, exposing the bony palate. This maneuver can be performed before or after the flap is raised. Following this, the central palatal mucoperiosteum is raised using a relatively narrow periosteal elevator. With a thin straight osteotome or an oscillating saw, the central portion of the maxilla is split between the incisors, and this is continued along the hard palate. Care is taken not to injure the palatal mucoperiosteum. Once this is done, the maxilla can be mobilized using the mobilizing forceps, and the segment can be swung laterally to expose the clival area (Fig. 1C). With this approach,

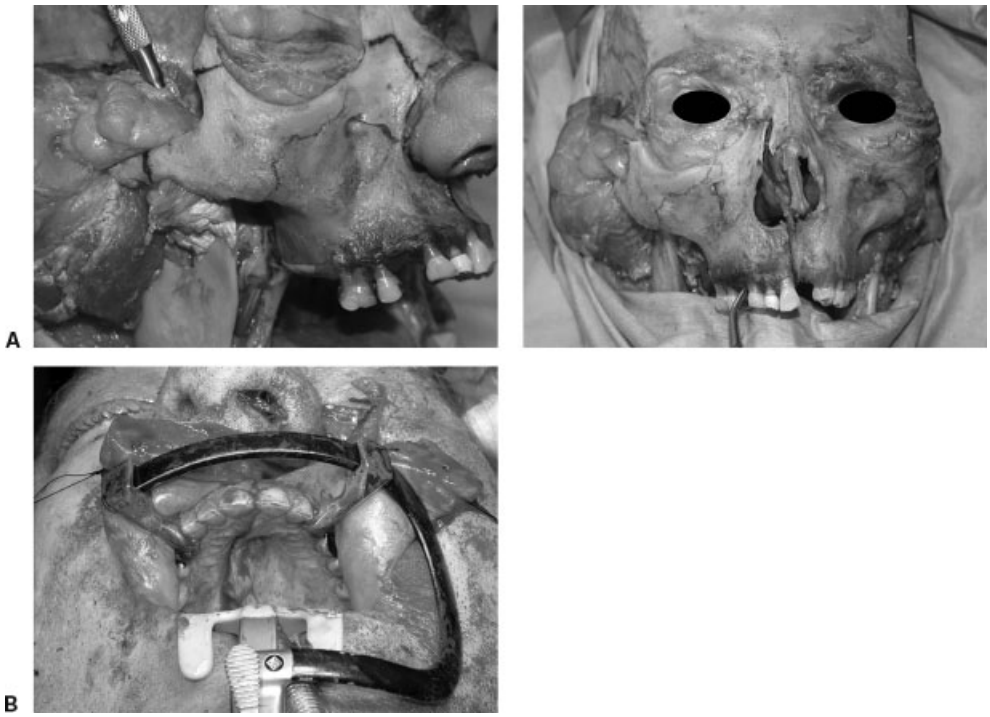

Figure 1 (A) The osteotomy is outlined on the maxilla, vertically in the nasal area, vertically in the zygomatic arch, and transversely in the lateral wall of the orbit, and then continues around the floor of the orbit and the palate is split. (B) The incision on the palate is taken across onto the side of the palate, which will not be mobilized. From this incision, the palatal mucosa is elevated to the area where the palatal split has been performed—the palatal overlap flap.

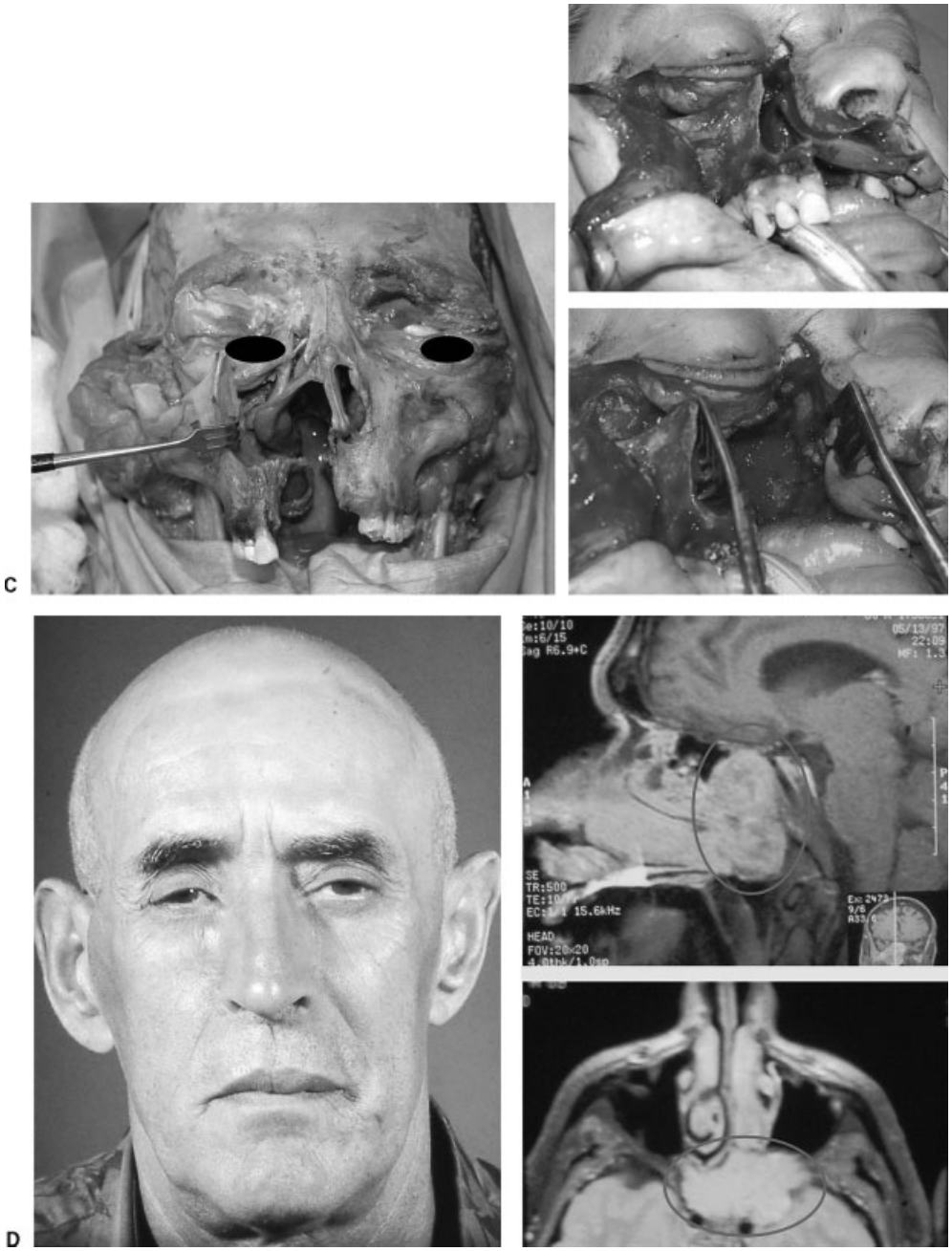

Figure 1 (*Continued*) (C) The mobilization of the segment of maxilla and orbit is now completed, and with the self-retaining retractor, good exposure can be obtained for excision of the skull base lesion. (D) This patient has a central skull base lesion that is amenable to resection by the approach described.

the tumor can be resected under good vision. There really is no limit to anteroposterior resection apart from the anatomy. The end result has always been aesthetically acceptable (Fig. 1D and E).

Frequently, a coronal flap needs to be turned down to provide optimal exposure. This is an aid not just to the exposure but also for the reconstruction. A galeal pericranial flap is elevated, based inferiorly

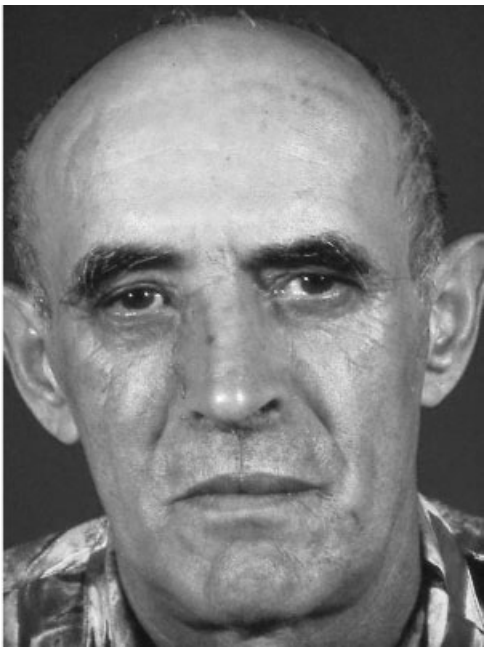

E

Figure 1 (*Continued*) (E) The result following closure of the exposure incisions together with plating of the maxillary segment to the contralateral side and to the stable lateral orbital wall superiorly.

in the glabellar area. This is an axial flap that is well vascularized. This is fed down into the central defect to provide vascularity to the exposed bony surfaces. This may or may not be necessary but it provides a very well-vascularized cover for any exposed bone. The maxilla is stabilized with plates or wires.

An additional safety measure is the palatal overlap flap described above. This is wider than the distance from the teeth to the palatal osteotomy, and when this flap is placed back in position, it covers the osteotomy and is securely sutured to the edge of the palatal mucosa over the intact palatal shelf. This arrangement prevents any ascending infection from the oral to nasal cavity or to the intracranial area. Perhaps just as important, it provides a secure closure and, in our experience, there is never a problem of palatal fistula. It is this technique that we want to emphasize as it increases the safety of the procedure.

A further point is that the extent of the maxillary segment design and mobilization can be related to the position and size of the tumor. When planning this approach, it is necessary to make sure that there is a reasonable lateral attachment of soft tissue to provide vascularization.

In the past, exposure was provided by removal of segments of bone.[11] These were replaced and stabilized at the end of the resection. Most times, this technique worked reasonably well, but segments could be lost due to lack of blood supply and/or infection with disastrous consequences. It should also be appreciated that some of these cases have been or will be treated with adjuvant radiation therapy, and thus the preservation of vascularity is very important. It is also our feeling that the galeofrontalis flap provides further security in terms of ascending infection.[12] After the resection, the flap is tacked to the bone of the cribriform area using drill holes. Care is taken to make sure it overlaps the edge of the bony defect. The flap is then further stabilized by the forward movement of the frontal lobes. This prevents ascending infection by supplying a vascularized barrier to this area.

In terms of the extent of maxilla to be swung, the initial concept was to perform a hemi LeFort III.[13–16] This was simply a standard osteotomy in craniofacial deformity surgery, and it was used because of familiarity. However, as our experience has increased, it was realized that a smaller segment of the orbit and maxilla could be swung laterally without compromising exposure. At the dentition level, the whole hemimaxilla (i.e., LeFort I segment) forms the base of the segment. This is not absolutely necessary, but the interincisal osteotomy is convenient and allows easy alignment and fixation for reconstruction because the central bone of the alveolus is dense and can be plated or wired. If this stabilization regimen is followed, it is easier to end up with the correct dental alignment.

The palatal flap described above is thought to be important. It allows the suture line for the flap reattachment to be situated over the palate laterally on the undisturbed side. In this way, it provides the most vascular, most stable, and most secure closure. Because of the position of the suture line, there is no possibility of a through-and-through injury. With

Figure 2 (A,B) A patient with a central skull base tumor.

this arrangement, it is unlikely, if not impossible, for a fistula to occur (Fig. 1B).

The other aspect to be considered is dental occlusion; with careful alignment of the alveolus and nasal spine segments with solid fixation, this is not a problem. A small compression plate applied to the alveolus to stabilize the central vertical osteotomy is advocated. It is inadvisable to trust a wire in this situation, as the repair is less stable. Intermaxillary fixation should be avoided and it is unnecessary; leaving the ability to open the mouth is safer and more comfortable for the patient.

Is the galeofrontalis flap absolutely necessary? The answer is probably not, but it is easy to elevate, based inferiorly. It brings vascularity to the denuded areas of the maxilla and to the osteotomies, which is

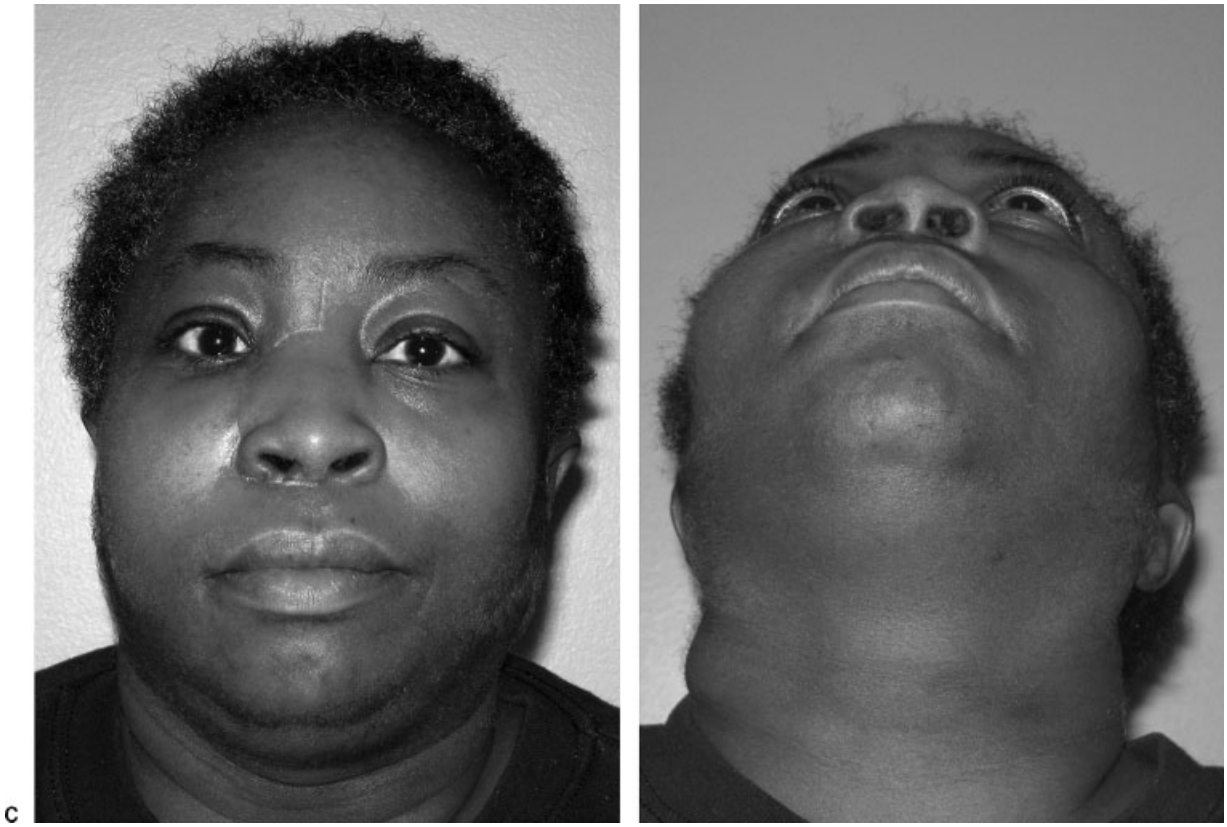

Figure 2 (*Continued*) (C) Six months following resection shows a very acceptable cosmetic result.

an advantage in terms of healing. Our studies of this flap not only have shown it to be well vascularized but, in addition, it can also carry bone, which also has been shown to be well vascularized. The best example of this was a complete reconstruction of a postradiation resected total mandible using a full-thickness fronto-temporal bone flap pedicled on the temporal galea.

CONCLUSION

The main purpose of this short article is to introduce further sophistication into skull base surgery. The maxillary osteotomy can be tailored to the exposure required by the neurosurgeon in his or her approach to the clivus and to the central anterior skull base in general. In the method described, we do not use a vertical central forehead incision. This is much appreciated by our patients. The careful alignment of the incisors necessitates little in the way of dental rehabilitation. In fact, the latter has not been necessary.

The solid fixation, the palatal flap technique, and the galeofrontalis flap all combine to make this a virtually complication-free procedure. The end result, as shown in the cases presented, can be very acceptable (Figs. 2 and 3).

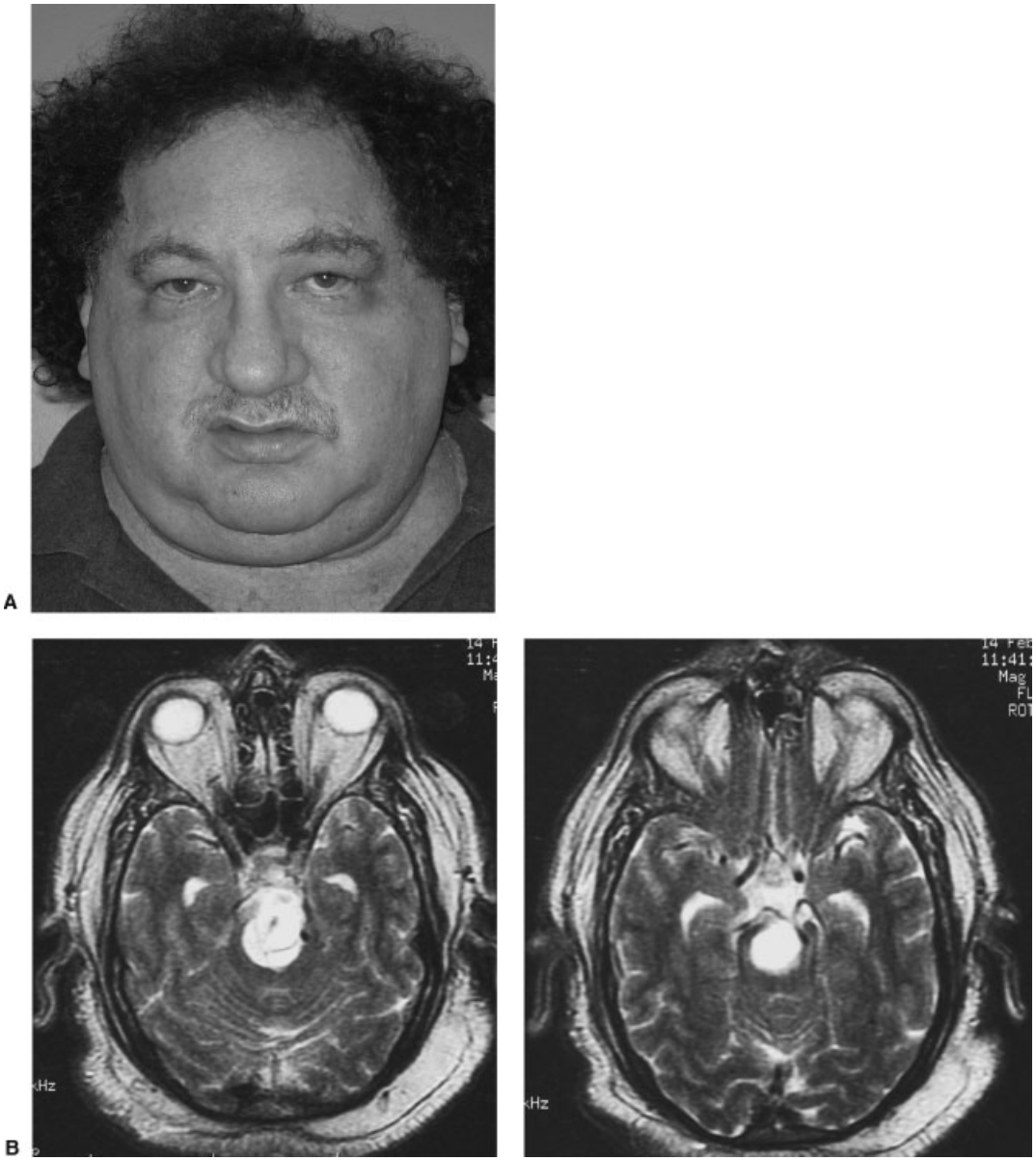

Figure 3 (A,B) Patient presenting with a skull base tumor shown radiologically in B.

Figure 3 (*Continued*) (C) The patient's appearance at 1 month postresection.

REFERENCES

1. Ammirati M, Bernardo A. Analytical evaluation of complex anterior approaches to the cranial base: an anatomic study. Neurosurgery 1998;43:1398–1407
2. Jackson IT, Marsh WR, Bite U, Hide TAH. Craniofacial osteotomies to facilitate skull base tumor resection. Br J Plast Surg 1986;39:153–160
3. Jackson IT. Craniofacial approach to tumors of the head and neck. Clin Plast Surg 1985;12:375–388
4. Jackson IT, Hide TAH. A systematic approach to tumors of the base of the skull. J Maxillofac Surg 1982;10:92–98
5. Ammirati M, Ma J, Cheatham ML, Mei ZT, Bloch J, Becker DP. The mandibular swing-transcervical approach to the skull base: anatomical study. J Neurosurg 1993;78: 673–681
6. Pieper DR, LaRouere M, Jackson IT. Operative management of skull base malignancies: choosing the appropriate approach. Neurosurg Focus 2002;12:1–8
7. Lam KH, Lau WF, Yue CP, Wei WI. Maxillary swing approach to the orbit. Head Neck 1991;13:107–113
8. Tessier P. Inferior orbitotomy: a new approach to the orbital floor. Clin Plast Surg 1982;9:569–575
9. Maroon JC, Kennerdell JS. Surgical approaches to the orbit: indications and techniques. J Neurosurg 1984;60: 1226–1235
10. Rhoton AL Jr. The orbit. Neurosurgery 2002;51(suppl): 303–334
11. Fearon JA, Munro IR, Bruce DA. Transfacial approaches to the cranial base. Clin Plast Surg 1995;22: 483–490
12. Sekhar LN, Schramm V L Jr, Jones NF. Operative management of large neoplasms of the lateral and posterior cranial base. In: Sekhar LN, Schramm VL Jr, eds. Tumors of the Cranial Base: Diagnosis and Treatment. Mount Kisko, NY: Futura; 1987
13. Sekhar LN, Sen CN. Anterior and lateral basal approaches to the clivus. Contemp Neurosurg 1989;11:1–8
14. Janecka IP, Chandranath S, Sekhar LN, Nuss DW. Facial translocation approach to nasopharynx, clivus, and infratemporal fossa. In Sekhar LN, Schramm VL Jr, eds. *Surgery of Cranial Base Tumors.*. New York: Raven; 1993: 245–260
15. Shekar LN, Chandranath S, Snyderman CH, Janecka I. Anterior, anterolateral, and lateral approaches to extradural petroclival tumors. In: Sekhar LN, Schramm VL Jr, eds. Surgery of Cranial Base Tumors. New York: Raven Press; 1993:157–224
16. Crockard HA. The transmaxillary approach to the clivus. In: Sekhar LN, Schramm VL Jr, eds. Surgery of Cranial Base Tumors. New York: Raven Press; 1993: 235–244