Surgical Techniques

A Modification to the Manouguian Aortoplasty

for Biological Valve Implantation in Patients with Small (≤19 mm) Aortic Anuli—Rationale and Benefit

Andreas Borowski, MD
Muhammed Kurt, MD

Enlargement of a small aortic root using the Manouguian technique for biological valve implantation can be challenging when rigid, severely calcified noncoronary parts of the aortic anulus are encountered in combination with outsized heights of interleaflet triangles. To maximize the efficacy of the Manouguian technique, we applied a modification—the rationale, technical details, and benefits of which we describe herein. ***(Tex Heart Inst J 2008;35(4):425-7)***

The posterior root enlargement as described by Manouguian and Seybold-Epting[1] remains an attractive and relatively simple method to avoid or alleviate patient–prosthesis mismatch for patients in whom the implantation of stentless or mechanical valves is inadvisable. In the Manouguian technique, the aortic anulus is divided in the area of the noncoronary cusp, and the incision is extended into the anterior mitral leaflet. The aortic root is then enlarged by inserting a wedge-shaped patch into the partially split anterior mitral leaflet and the ascending aorta.

However, the semilunar shape of the aortic leaflet attachments—in combination with a calcified anulus and high interleaflet triangles—can create technical difficulties in terms of tensionless placement of the prosthetic valve. When the aortic anulus and sinus area are calcified and nonpliable, the surgeon can encounter considerable problems in adapting the anulus to the horizontal structure of the prosthetic ring; the solution, too often, is to use a prosthetic valve of a size smaller than the patient needs.

As a remedy, we modified the Manouguian technique and applied this modification routinely in patients whose aortic anulus measured 19 mm or less in diameter.

Key words: *Aortic valve/surgery; bioprosthesis; heart valve prosthesis; prosthesis design; prosthesis fitting*

From: *Department of Thoracic & Cardiovascular Surgery, University of Düsseldorf, 40255 Düsseldorf, Germany*

Address for reprints: *Andreas Borowski, MD, Department of Thoracic & Cardiovascular Surgery, University of Düsseldorf, Moorenstrasse 5, 40255 Düsseldorf, Germany*

E-mail: Borowski@med.uni-duesseldorf.de

© 2008 by the Texas Heart® Institute, Houston

Surgical Technique

We used standard cardioplegic arrest, partially transected the aorta in typical fashion, excised the aortic valve, and débrided calcifications from the anulus. The aortic incision was extended through the fibrous origin in the anterior leaflet of the mitral valve approximately 1 cm below the aortic anulus, without entering the left atrium.

At variance from the original Manouguian technique, the noncoronary part of the anulus was then resected subtotally, along with a large adjacent area of the noncoronary sinus. We left intact the area of the commissures and took particular care to avoid injury to the atrioventricular conduction tissue while resecting the anulus in the area of the fibrous right trigonum. We then inserted in place a double-velour, wedge-shaped Dacron patch cut to a generous size from a standard 20-mm Hemashield® tube graft (Boston Scientific Corporation; Natick, Mass) and sewed it, in the first instance, up to a level slightly above the commissures, using simple running 4-0 Prolene suture. Figure 1 is a schematic drawing of the extended aortoplasty. The prosthetic valve was then implanted in a supra-annular position with interrupted 2-0 Ethibond mattress sutures (Ethicon Products Worldwide, a Johnson & Johnson Gateway® company; Miami Lakes, Fla). Teflon pledgets were placed outside the aorta within the Dacron patch, and, in typical fashion, within the aorta along the aortic anulus. The stitching line within the Dacron patch was then level with the tops of both commissures.

When this was done, a "1-size-up" biological valve was implanted (1 size larger than is possible with the conventional Manouguian procedure). After the valve was tied in place, the left margin of the remainder of the Dacron patch was trimmed in the ver-

tical direction, and the patch was fixed in the aortotomy incision.

Using this modification, we operated on 21 consecutive patients who were at risk of patient–prosthesis mismatch and who had an unfavorable risk-to-benefit ratio for implantation of a stentless valve. In Table I, we present perioperative and other data on these patients. In regard to the extent of anulus enlargement, most of our patients had a native anulus of less than 19 mm in diameter, so we assumed a native anulus circumference of less than 59 mm. After the extended aortoplasty, the orifice at the implant level was at least 21 to 23 mm in diameter in 18 patients, and it was 23 to 25 mm in diameter in the remaining 3 patients, which corresponds on average to circumferences of 69 mm and 75 mm, respectively. Therefore, it is safe to assume that aortoplasty resulted in anular-circumference enlargements of approximately 10 mm. The described modification enabled us to implant biological valves of 1 or perhaps 2 sizes larger than the original anulus could accommodate.

TABLE I. Characteristics of the 21 Patients

Mean age (range), yr	71 (45–92)
Women	17 (81%)
Mean body mass index (range)	29.4 (22.6–40.3)
Mean body surface area (range), m^2	1.77 (1.5–2.4)
Mean body weight (range), kg	79 (55–129)
Aortic valve replacement with 21-mm bioprosthesis	18
Aortic valve replacement with 23-mm bioprosthesis	3
Concomitant CABG (1–5 grafts)	17 (81%)
Concomitant myectomy	6 (28%)
Mean projected iEOA (range), cm^2/m^2	0.62 (0.45–0.78)
Mean postoperative iEOA (range), cm^2/m^2	0.75 (0.54–0.92)
Moderate postoperative PPM (iEOA 0.65–0.85)	14 (67%)
Severe postoperative PPM (iEOA <0.65)	1 (5%)
Mean aortic cross-clamp time (range), min	88 (60–132)
Mean ECC-T (range), min	125 (78–192)
IABP support	3 (14%)
Deaths	0

CABG = coronary artery bypass grafting; ECC-T = time (duration) of extracorporeal circulation; IABP = intra-aortic balloon counterpulsation; iEOA = indexed effective orifice area; PPM = patient–prosthesis mismatch

Discussion

In cases in which the aortic root is very small (≤19 mm), the choice of aortic valve type and of root-enlargement method may be difficult, and the operative strategy should be planned carefully before surgery.

In order to avoid patient–prosthesis mismatch, Pibarot and their colleagues[2,3] have presented a simple formula whereby multiplying body surface area (BSA) by 0.85 cm^2/m^2 yields the minimum effective orifice area for implantation of a prosthetic valve. For a given patient with a BSA of 1.8 m^2, the projected effective orifice area is 1.53 cm^2, which means that patient–prosthesis mismatch can be avoided by using either a mechanical prosthetic valve with a labeled size of 19 mm (such as a SJM Regent®—St. Jude Medical, Inc.; St. Paul, Minn), or a stentless biological valve with a size of 21 mm (such as a Medtronic Freestyle®—Medtronic, Inc.; Minneapolis, Minn), or a stented biological valve with a size of 23 mm (such as the Carpentier-Edwards PERIMOUNT—Edwards Lifesciences LLC; Irvine, Calif).[4]

The surgeon's dilemma emerges especially in planning treatment for elderly patients who are scheduled for complex concomitant procedures that carry the prospect of long cross-clamp times: in these patients, the mechanical valve is an altogether untenable option, and the stentless valve carries an unfavorable risk-to-benefit ratio, due to the significantly longer cross-clamp times. According to recently published data,[5,6] stentless valves have shown no definitively proven benefits. The patient's overall clinical condition and risk-to-benefit ratio should be considered, in order to avoid an excellent technical result at the expense of morbidity and death.

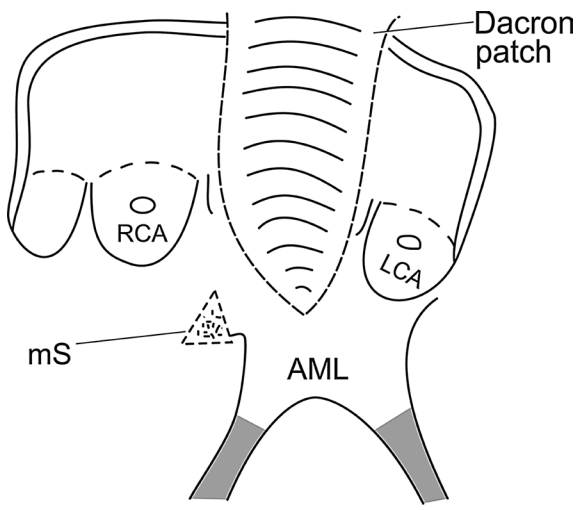

Fig. 1 *Schematic drawing of the extended aortoplasty.*

AML = anterior mitral leaflet; LCA = orifice of the left coronary artery; mS = membranous septum; RCA = orifice of the right coronary artery

Our modification of the Manouguian procedure is derived from the concept published by Anderson and associates[7]: the arrangement of the aortic valve is not ringlike but semilunar. We believe that this semilunar arrangement requires that a surgeon conform to its natural design when he or she attempts to accommodate the aortic anulus to the horizontal structure of the prosthetic ring, should the anulus be nonpliable due to calcifications and should the height of the interleaflet triangles exceed that of the anulus. This applies particularly to the noncoronary part of the anulus, where the outflow tract has a fibrous supporting structure in continuity with that of the mitral leaflet. Our subtotal resection of the anulus with a large portion of the adjacent sinus area enables tensionless implantation of the prosthetic valve and avoids obstruction to blood flow by remnants of the anulus and by pledgeted suture material within the outflow tract.

Although the technique as we have described it here is very simple to perform, risk of injury of the atrioventricular node should be borne in mind. Awareness of the spatial relationship between the conduction system and the anulus enables the surgeon to easily avoid this anatomic pitfall.

In using our modification of the Manouguian technique, the surgeon will find that aortic cross-clamp times, even when this procedure is performed in combination with concomitant procedures, are notably shorter than those necessary for the implantation of stentless valves.[8] Moreover, the effective orifice areas of the implanted biologic stented valves are comparable to those of biologic stentless valves that could have been implanted without root enlargement.

In conclusion, our data lead us to believe that this modification of the original Manouguian procedure is highly effective and easy to perform. We strongly recommend it for patients who are at risk of patient–prosthesis mismatch and who need biologic valves and shorter cross-clamp times.

References

1. Manouguian S, Seybold-Epting W. Patch enlargement of the aortic valve ring by extending the aortic incision into the anterior mitral leaflet. New operative technique. J Thorac Cardiovasc Surg 1979;78(3):402-12.
2. Pibarot P, Dumesnil JG, Cartier PC, Metras J, Lemieux MD. Patient-prosthesis mismatch can be predicted at the time of operation. Ann Thorac Surg 2001;71(5 Suppl):S265-8.
3. Pibarot P, Dumesnil JG. Prosthesis-patient mismatch: definition, clinical impact, and prevention. Heart 2006;92(8): 1022-9.
4. Muneretto C, Bisleri G, Negri A, Manfredi J. The concept of patient-prosthesis mismatch. J Heart Valve Dis 2004;13 Suppl 1:S59-62.
5. Kallikourdis A, Jacob S. Is a stentless aortic valve superior to conventional bioprosthetic valves for aortic valve replacement? Interact Cardiovasc Thorac Surg 2007;6(5):665-72.
6. de Kerchove L, Glineur D, El Khoury G, Noirhomme P. Stentless valves for aortic valve replacement: where do we stand? Curr Opin Cardiol 2007;22(2):96-103.
7. Anderson RH, Devine WA, Ho SY, Smith A, McKay R. The myth of the aortic annulus: the anatomy of the subaortic outflow tract. Ann Thorac Surg 1991;52(3):640-6.
8. Bach DS, Cartier PC, Kon ND, Johnson KG, Deeb GM, Doty DB. Impact of implant technique following freestyle stentless aortic valve replacement. Ann Thorac Surg 2002;74 (4):1107-14.