Case Reports

Repair of Coarctation-Related Aortic Arch Aneurysm and Ventricular Septal Defect

in an Adolescent

Cuneyt Narin, MD
Erdal Ege, MD
Atilla Orhan, MD
Mehmet Yeniterzi, MD

A saccular aortic arch aneurysm that is secondary to aortic arch coarctation and that is accompanied by a ventricular septal defect is a rare combination in the adolescent patient. Total simultaneous repair of all of these conditions is desirable, because of the higher morbidity and mortality rates of staged procedures—particularly when resection of the saccular aneurysm is delayed.

Herein, we discuss the case of a 16-year-old boy who underwent simultaneous surgical correction of these malformations. With the aid of cardiopulmonary bypass on the beating heart, the coarctation and the aneurysmal segment were resected, and a tubular Dacron graft was interposed. The ascending aorta and femoral artery were both then cannulated to ensure whole-body perfusion during cardiopulmonary bypass. The ventricular septal defect was closed with the patient under cardioplegic arrest. After 10 days, he was discharged from the hospital without sequelae. We conclude that single-staged repair of cardiac abnormalities and of an aortic arch aneurysm that is secondary to coarctation of the aortic arch can be performed safely and effectively in adolescent and adult patients by use of our technique. ***(Tex Heart Inst J 2008;35(4):466-9)***

Key words: *Aorta/surgery; aortic aneurysm/physiopathology/surgery/ultrasonography; aortic coarctation/complications/physiopathology/surgery/ultrasonography; coronary disease/surgery; magnetic resonance angiography; methods; time factors*

From: *Department of Cardiovascular Surgery, Meram Medical School, Selcuk University, 42080 Konya, Turkey*

Address for reprints: *Cuneyt Narin, MD, Department of Cardiovascular Surgery, Meram Medical School, Selcuk University, 42080 Konya, Turkey*

E-mail: cunarin@yahoo.com

© 2008 by the Texas Heart® Institute, Houston

Unrepaired coarctation of the aorta can lead to hypertensive cardiovascular sequelae, such as coronary disease, heart failure, stroke, aortic dissection or rupture, and premature death.[1] Although narrowing of the aortic arch is sometimes seen when surgery is performed on congenital cardiac abnormalities, aortic coarctation that persists into adulthood is unusual. Coarctation that originates between the arch vessels is rare, constituting approximately 1% of all coarctation cases.[2] Aortic coarctation is sometimes accompanied by a fusiform or saccular aneurysm, which is either congenital or secondary to the hemodynamic disturbance caused by the coarctation. Native aortic coarctation alone is usually repaired surgically through a left thoracotomy, but aortic arch coarctation with saccular aneurysms and concomitant cardiac disorders in adolescent patients still present dilemmas for the surgeons.[3] To decrease potential complications of anatomic repair, various techniques have been proposed,[3,4] such as extra-anatomic ascending aorta-to-descending aorta bypass, or the use of deep hypothermic circulatory arrest during a simultaneous or staged surgical approach. In our patient, the single-staged repair of a ventricular septal defect (VSD) and a large saccular aortic arch aneurysm that was secondary to an unusually located coarctation of the aortic arch was carried out via median sternotomy.

Case Report

In September 2006, a 16-year-old boy was admitted to our hospital because of palpitations, occasional chest pain, and a cough of 2 years' duration. His medical history was not significant. Upon admission to the hospital, the patient's condition was hemodynamically stable. His arterial blood pressure was 135/75 mmHg in the right upper extremity, and 80/40 mmHg in the left upper extremity and both lower extremities. His pulse rate was 84 beats/min, and his right radial pulse was felt more strongly than the pulses in the upper left side and the lower extremities. Cardiac auscultation revealed a grade 3/6 pansystolic murmur at the mesocardiac point, and a systolic murmur in the interscapular area. Resting electrocardiography showed normal sinus

rhythm. Two-dimensional transthoracic echocardiography revealed coarctation of the aortic arch with a gradient of 55 mmHg, and a saccular dilation of the aortic arch at the segment distal to the coarctation. In addition, a perimembranous VSD was identified. Neither pulmonary hypertension nor right ventricular dilation was detected. Magnetic resonance angiography (MRA) showed the widened ascending aorta, a saccular aortic aneurysm, and a dimension of 18 mm at the isthmus of the aneurysm in the middle of the aortic arch. As measured craniocaudally, the aneurysm was 60 mm long (Fig. 1A). The aneurysm and coarctation were proximal to the left subclavian artery, which anomalously originated from the descending aorta. The brachiocephalic artery and the left carotid artery both originated from the aorta and displayed a normal branching pattern before the aneurysm. There were notable collateral vessels in the coarctation area. Cardiac catheterization was deemed unnecessary, because enough information was obtained by echocardiography and MRA.

Surgery was performed via median sternotomy. Bicaval venous cannulation and cannulation of both the ascending aorta and the left femoral artery were performed to enable whole-body perfusion during cardiopulmonary bypass (CPB). After the institution of CPB, the left ventricle was vented by use of a left superior pulmonary venting cannula, and the patient's rectal temperature was kept at 32 °C. Aortic clamps were placed proximal and distal to the aneurysm and the coarctation at the aortic arch (Fig. 1B). During the procedure, the proximal clamp was placed distal to the origin of the left common carotid artery, and the distal clamp was placed proximal to the origin of the left subclavian artery at the aortic arch. While all arch branches and the thoracoabdominal aorta were being perfused during CPB on the beating heart, the aneurysmal segment was resected and replaced with a 14-mm tubular Dacron graft (Fig. 2A). The patient's temperature was lowered to 29 °C, the ascending aorta was cross-clamped, and cardioplegic solution was administered in antegrade fashion for myocardial protection. The VSD was repaired with a Dacron patch through the right atrium. The patient was uneventfully weaned from CPB. After slightly excessive drainage and moderate hemodynamic instability prolonged his intensive care unit stay, he was transferred to a ward on postoperative day 4. He was discharged from the hospital on postoperative day 10. At his 13-month follow-up examination, he was asymptomatic, and MRA revealed normal anatomy of the aortic arch (Fig. 2B).

Discussion

Aortic coarctation is usually diagnosed and treated when patients are children, and complications are rarely seen.[3,5] However, if coarctation of the aorta is left untreated, 25% of such patients will die by the end of their 2nd decade of life, 49% by the end of their 3rd decade, and approximately 90% by the age of 50 years. Causes of death in patients with aortic coarctation are aortic rupture, aortic dissection, congestive heart failure, bacterial endocarditis, and intracranial hemorrhage.[6]

Although aortic coarctation often occurs as an isolated malformation, it can also be associated with other cardiac anomalies, including VSD.[2] Coarctation of the aorta is sometimes accompanied by fusiform or saccular aortic aneurysms, which are either congenital or sec-

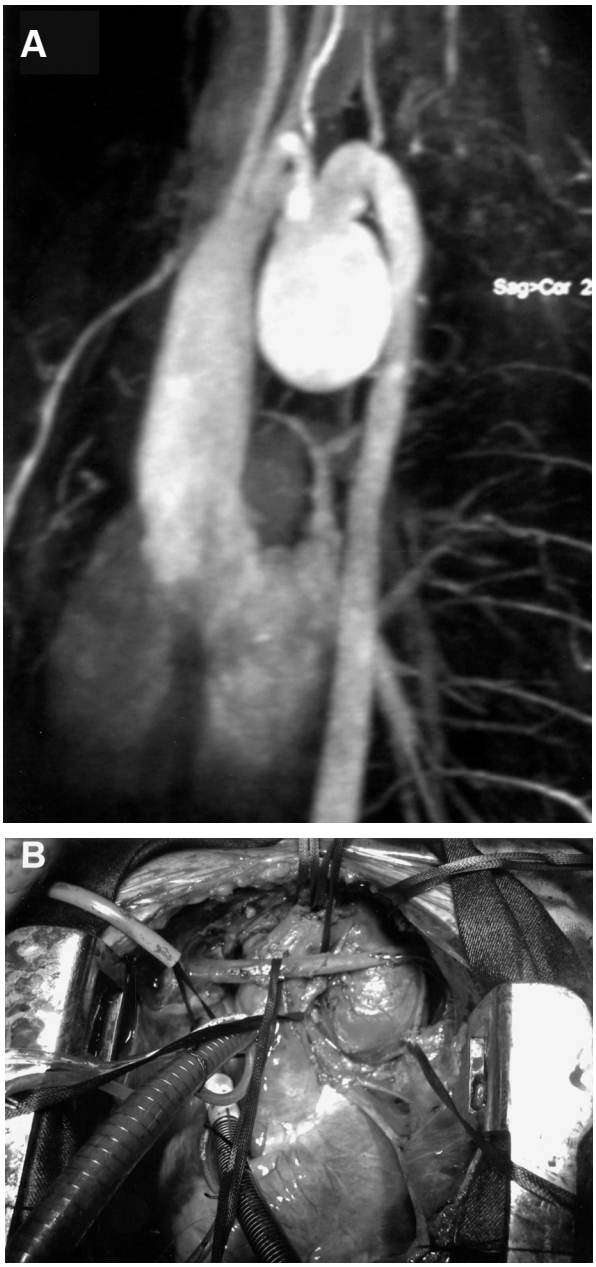

Fig. 1 ***A****) Magnetic resonance angiography shows a large saccular aortic aneurysm and aortic coarctation, combined with a ventricular septal defect.* ***B****) Intraoperative photograph shows the large saccular aneurysm of the aortic arch.*

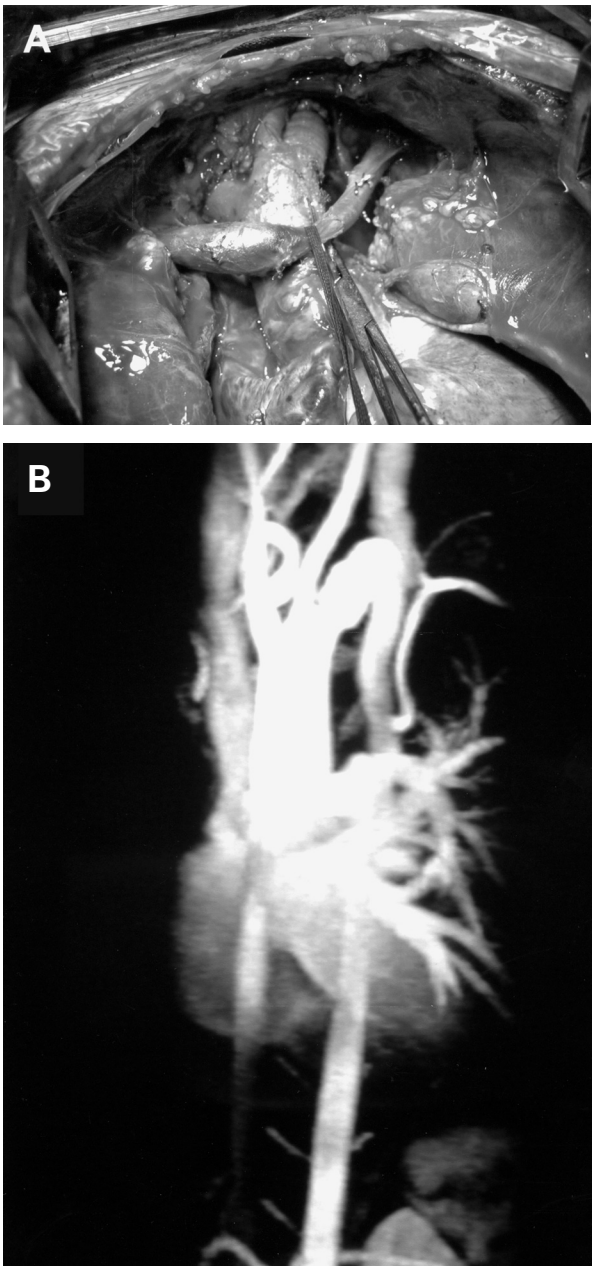

Fig. 2 ***A****) Intraoperative photograph of the completed repair of the aortic arch by use of a tubular Dacron graft.* ***B****) Postoperative magnetic resonance angiography shows complete repair of the lesions.*

ondary to the hemodynamic disturbances caused by the coarctation. Although coarctation of the aorta can be associated with either type of aneurysm, saccular aortic aneurysms distal to the coarcted segment are relatively rare, and the data about them have been confined to a few case reports.[5] Vascular surgeons generally believe that saccular aortic aneurysms are more likely to rupture than typical fusiform aneurysms.[7] Rapid repair is indicated for symptomatic saccular aneurysms, and intervention is usually advocated even when they are asymptomatic, because of the general belief that their shape makes them prone to rupture.[7]

Although diagnosis can usually be performed on a clinical basis, imaging techniques are essential in order to evaluate the anatomy of the lesion and to find related lesions, such as cardiac malformations.[6] Especially in adult patients with aortic coarctation, MRA is increasingly being used as a 1st-line investigatory method before cardiac catheterization. Magnetic resonance angiography can reliably define coarctation of the aorta and show aortic complications, such as aneurysmal formation, and MRA provides excellent definition of the size of the aneurysm. Computed tomography, an alternative to MRA, also enables accurate evaluation of an aneurysm's shape and its spatial relationships to the branch vessels, and enables the evaluation of extravasated blood in instances of acute or subacute rupture.[5]

Different surgical approaches have been described for the treatment of aortic coarctation. One is to perform the operation for the coarctation and the additional cardiovascular operation as staged procedures.[4] Another option is single-staged repair of the combined condition via a median sternotomy.[3,8] Mulay and colleagues[4] reported on 3 patients who underwent staged procedures—the intracardiac repair first, followed by repair of the coarctation after 6 weeks at the earliest. The authors suggested that simultaneous repair would have caused a sudden decrease in systemic vascular resistance, whereas staged repair enabled recovery of the myocardium and the redistribution of coronary blood flow during the interval between the 2 operations. The authors also pointed out that lower-body perfusion was not of great concern during CPB because of the good collateral circulation in their 3 adult patients.

Vijayanagar and co-authors[9] were the first to describe aortic valve replacement and concomitant ascending aorta-to-descending aorta bypass through the posterior pericardium with placement of the graft around the left margin of the heart, entirely through median sternotomy. Thereafter, surgeons undertook varying versions of this single-staged repair method. Differences between the methods regard the distal anastomosis site, such as the descending aorta, the abdominal aorta, or the femoral artery. Morris and associates[8] reported the single-staged repair of aortic coarctation and accompanying cardiac disorders in 3 patients. The surgeries consisted of intrapericardial ascending aorta-to-descending aorta bypass and concomitant correction of the cardiac lesions. Those authors concluded that operating on the cardiac defect without confronting the substantial coarctation could have led to considerable underperfusion of organs distal to the coarctation, which would have placed the left ventricle under a severe pressure load from late hypertension and incurred the risk of congestive heart failure. Yilmaz and colleagues[3] reported on their 4 patients who each underwent a single-staged

procedure: anatomic left-sided short aortic bypass for the aortic coarctation through median sternotomy, with the use of deep hypothermic circulatory arrest and concomitant repair of the cardiac lesion. Inotropic agents were administered carefully during weaning from CPB in order to provide peripheral vascular resistance after bypass. The authors stated that the risk of kinking of the aortic bypass graft might be lowered by using anatomic left-sided aortic bypass. Heper and co-authors[10] reported the case of a 20-year-old man who had an aneurysm of the ascending aorta that was secondary to aortic coarctation and aortic insufficiency. They first performed balloon angioplasty for the coarctation in order to reduce afterload and hypertension, and to facilitate femoral artery cannulation for CPB. The subsequent surgery consisted of aortic valve replacement and replacement of the ascending aorta with a tubular Dacron graft. The authors stated that their approach prevented underperfusion of the abdomen and any need for either a 2nd stage of repair or a more invasive single-staged repair.

Since the early 1990s, endovascular grafts have been widely used in the treatment of aneurysms.[8] In our patient, however, surgery was the technique of choice, because of the other cardiac anomalies and the location of the aortic malformation. We preferred the single-staged, on-pump surgical technique via median sternotomy because of the saccular aneurysm of the aortic arch secondary to the unusual location of the aortic coarctation, and the accompanying VSD. Accordingly, neither a staged operation nor a single-staged procedure with ascending aorta-to-descending aorta bypass was necessary.

During such a surgical procedure, the chief challenge is arterial cannulation, because of the aortic aneurysm that is secondary to aortic coarctation. If cannulation is performed only via the femoral artery, perfusional problems can result, especially in the upper extremities and the brain. If cannulation is performed only via the ascending aorta or the right axillary artery, perfusion of the mesenteric and renal arteries can be compromised. Conversely, when the femoral artery is cannulated together with the ascending aorta or the right axillary artery, whole-body perfusion can be provided, and adverse perfusional sequelae can be avoided during surgery on the aortic arch.[10] Applying whole-body perfusion enabled us to repair the aortic arch on the beating heart with the aid of CPB. Our patient tolerated the single-staged repair well, and he experienced no serious postoperative myocardial functional impairment or decreased systemic vascular tone.

We conclude that adolescent and adult patients who have cardiac malformations along with aneurysm of the aortic arch that is secondary to coarctation can be safely and efficaciously treated via a single-staged approach. In such circumstances, whole-body perfusion by means of ascending aortic and femoral artery cannulation can provide superior perfusion to the organs.

References

1. Cohen M, Fuster V, Steele PM, Driscoll D, McGoon DC. Coarctation of the aorta. Long-term follow-up and prediction of outcome after surgical correction. Circulation 1989;80(4):840-5.
2. Ikonomidis JS, Kim PY, Crawford FA Jr. Repair of aortic arch coarctation and innominate artery aneurysm with branched Dacron graft. J Thorac Cardiovasc Surg 2004;127(2):579-81.
3. Yilmaz M, Polat B, Saba D. Single-stage repair of adult aortic coarctation and concomitant cardiovascular pathologies: a new alternative surgical approach. J Cardiothorac Surg 2006;1:18.
4. Mulay AV, Ashraf S, Watterson KG. Two-stage repair of adult coarctation of the aorta with congenital valvular lesions. Ann Thorac Surg 1997;64(5):1309-11.
5. Celik T, Iyisoy A, Kursaklioglu H, Unlu M, Kose S, Ozmen N, Isik E. A large calcified saccular aneurysm in a patient with aortic coarctation. Int J Cardiovasc Imaging 2006;22(1):93-5.
6. Hiller N, Verstanding A, Simanovsky N. Coarctation of the aorta associated with aneurysm of the left subclavian artery. Br J Radiol 2004;77(916):335-7.
7. Taylor BV, Kalman PG. Saccular aortic aneurysms. Ann Vasc Surg 1999;13(6):555-9.
8. Morris RJ, Samuels LE, Brockman SK. Total simultaneous repair of coarctation and intracardiac pathology in adult patients. Ann Thorac Surg 1998;65(6):1698-702.
9. Vijayanagar R, Natarajan P, Eckstein PF, Bognolo DA, Toole JC. Aortic valvular insufficiency and postductal aortic coarctation in the adult. Combined surgical management through median sternotomy: a new surgical approach. J Thorac Cardiovasc Surg 1980;79(2):266-8.
10. Heper G, Yorukoglu Y, Korkmaz ME. Clinical and hemodynamic follow-up of a patient after operation for dissection of an ascending aortic aneurysm secondary to coarctation of the aorta. Int Heart J 2005;46(6):1123-31.