Medical Devices

Retractable-Needle Catheters

An Update on Local Drug Delivery in Coronary Interventions

Paolo Angelini, MD
Wijay Bandula, MD

In the treatment of coronary artery disease, local delivery of pharmaceutical substances has long been a goal, yet the technology is still evolving. Coronary stents have become the predominant means of treating obstructive lesions, and the need for additional pharmacologic treatment is evidenced by the popularity of drug-eluting stents. Moreover, stents have residual limitations, in particular in-stent thrombosis and late restenosis. Investigators have recently proposed delivering coronary drugs by means of local injection devices. These innovative devices, which incorporate retractable needles at the tip of a catheter, appear to be ready for clinical testing. In addition to solving many of the limitations of drug-eluting stents, local injection devices may eventually enable interventional cardiologists to treat vulnerable plaques. Herein, we review the evolution and current status of local drug delivery in the coronary arteries, with an emphasis on novel catheters that have retractable needles. ***(Tex Heart Inst J 2008;35(4):419-24)***

Key words: *Cardiovascular agents/therapeutic use; coronary artery disease/economics; coronary disease/drug therapy; coronary restenosis/prevention & control/therapy; coronary stenosis/complications; delayed-action preparations/administration & dosage; drug delivery systems/instrumentation/methods; drug implants; equipment design; stents/adverse effects*

From: *Department of Cardiology (Dr. Angelini), Texas Heart Institute at St. Luke's Episcopal Hospital, Houston, Texas 77030; and Binlab, Inc. (Dr. Bandula), Webster, Texas 77598*

Dr. Angelini holds part of the patent rights for the local injection device manufactured by Binlab, Inc., of Webster, Texas. Dr. Bandula holds part of the patent rights for the same device; he is also Binlab's president and majority stockholder.

Address for reprints: *Paolo Angelini, MD, P.O. Box 20206, Houston, TX 77225-0206*

E-mail: pangelini@leachmancardiology.com

© 2008 by the Texas Heart® Institute, Houston

In the clinical practice of interventional cardiology, the idea has long been accepted that coronary artery disease (CAD) is chiefly (although not only) a local process, one best treated with local methods. Segmental coronary luminal stenoses, occlusions, or unstable plaques are the most favorable targets for interventions that are aimed at preventing or limiting manifestations of ischemia and myocardial loss, including arrhythmias, congestive heart failure, and death. Coronary interventional treatment has typically consisted of mechanical solutions—surgical bypass and angioplasty. Over the years, however, several systemic pharmaceutical treatments have been introduced to decrease recurrence, stabilize lesions, or cause disease regression at target sites.[1] Here, we review the evolution and current status of local drug delivery in the coronary arteries, with an emphasis on novel catheters that have retractable needles.

Stent-Angioplasty

In the late 1980s, angioplasty with the use of bare-metal stents (BMSs) was introduced to obviate the most serious limitations of stand-alone balloon angioplasty: acute elastic recoil, plaque ulceration or dissection, subacute negative vessel remodeling, and fibrocellular proliferation. Angioplasty with BMSs enabled physicians to optimize the early results of vascular recanalization while avoiding elastic recoil and preventing dissection and early reclosure.[2,3] Nevertheless, BMS-angioplasty did not solve the biological problems that were created by producing localized coronary trauma with a rigid, metallic device: rare, but catastrophic, postoperative acute stent thrombosis, and, more frequently, delayed in-stent restenosis. Eventually, systemic platelet antiaggregants, namely clopidogrel and aspirin, proved effective in significantly limiting early stent thrombosis.[2,3] Fibrocellular growth (mostly by means of cell proliferation and smooth-muscle-cell migration from the media level), platelet activation and aggregation, inflammation, and fibrin deposition were recognized as the mechanisms that initiate restenosis.[4,5]

Drug-Eluting Stents

Subacute in-stent restenosis was not treated effectively until the advent of drug-eluting stents (DESs), which deploy drugs that inhibit fibrocellular proliferation and migration.[6,7] These stents are covered with porous polymer coatings that absorb the chosen drug, transport it to the target site, and deliver it over a specified time interval. Such

stents are quite effective in repressing intimal growth; they lower the rate of restenosis (or late luminal loss) by 50% to 80%.[7-9] Nevertheless, their advent introduced or left unsolved the following limitations:

1) The cost of a stent increased approximately 3-fold.[10,11] This is a serious clinical and health-policy problem: multivessel CAD has evolved into a de facto indication for angioplasty, although stent-angioplasty in multiple-vessel disease is not yet approved by the U.S. Food and Drug Administration (FDA).[12]
2) The problem of restenosis was not totally resolved,[13] especially in cases involving complex lesions, which comprise up to 70% of lesions that are treated with DESs.[14-16] (Again, the FDA has never approved the deployment of any stent for the treatment of these lesions.)
3) With the use of DESs in complex lesions, the incidence of stent thrombosis increased significantly in complex lesions, both early and late (1 to 4 years) after stent deployment.[17,18]
4) As a result of the preceding 2 limitations, the probability of acute myocardial infarction or death after coronary-stent interventions did not lessen upon the use of DESs in comparison with BMSs.[15,16] Because DESs were designed to prevent major clinical events, this finding was sobering.[8]

Some Reasons for the Failure of Drug-Eluting Stents

The limitations of DESs are likely related to multiple factors:

1) Any coupling of a drug agent with a given device generates a long, expensive approval process, because drug agents must be specifically licensed for such use. The cost is inevitably transferred to the patient or to the health-maintenance system.
2) The stent's coating itself could cause biological interference. The coating may not be covered by a vital endothelium; when the coating eventually breaks down, the probability of inflammatory and thrombotic complications increases, as is evidenced by delayed fibrin deposition.[19,20]
3) Most DESs deliver the active drug endoluminally. This method of delivery likely inhibits endothelial migration and seeding onto the stent—a process that is thought to be essential in the prevention of stent thrombosis.[17,18]
4) After DES implantation, restenosis is usually focal,[7,8,13] unlike the diffuse restenosis that is commonly seen after the implantation of a BMS. This is likely caused by the specific conditions at the restenosis site:
   - Restenosis after DES implantation typically occurs at the level of severe (calcific) lesions that were not adequately dilated before stent deployment. Under these conditions, high-pressure balloon postdilation is frequently applied. This treatment may lead to compression in the coating, which could cause drug elution to occur too early and too quickly. During the healing phase after stenting, when the vessel is most vulnerable to restenosis, local drug availability may be inadequate.
   - Proliferative, diffuse CAD may require a larger amount of the inhibiting drug than is routinely carried by a DES, as in patients who have diabetes mellitus, long lesions, diffuse in-stent restenosis, or venous grafts. These patients still experience increased restenosis rates after DES use.[8,13,15,16,19,20]
   - At the site of DES implantation, side branches are at higher risk of restenosis, probably because of the presence of an unopposed stent and the likelihood of "snow-plowing" of the compressed atherosclerotic plaque.[12,14] In this circumstance, dispensing a higher dosage of the inhibiting drug(s) than is routinely available in a DES may be beneficial.
   - The edges of a DES—particularly the proximal edge—may also be sites of increased fibrocellular proliferation and could routinely require an increased drug concentration or longer duration of administration, especially if the arterial disease is diffuse.[8,15,16]
   - Manufacturing defects in the coating of an individual DES may also increase the risk of restenosis.[21]

Alternative Methods of Local Drug Administration

Local administration of pharmacologic agents, genes, or cells was an investigational goal even long before the introduction of DESs.[22] However, no single practical solution has been found. The following options have been tested:

1) The guiding catheter itself (Fig. 1) may be used for acute endoluminal delivery, as in the administration of thrombolytics or IIb/IIIa platelet-receptor inhibitors. Unfortunately, this simple approach has not proved effective for preventing restenosis. Prevention seems to require prolonged administration—possibly for an entire month, as has been suggested by the results of animal experiments.[23]
2) Different kinds of balloon catheters (Fig. 2) have been used in multiple ways (such as in leaky or porous balloons[24,25]) to deliver solution-carrying active substances locally to the target site. However, the balloon-catheter approach imparts quite a low efficiency of drug delivery (the ratio of the drug delivered into the vascular wall vs the total amount delivered), and the risk of intimal or endotheli-

al damage could be a limiting factor, especially in the presence of high-velocity jets. In addition, the treated artery becomes temporarily occluded during the delivery process.

3) Drugs have been applied directly on balloons or BMSs by means of various techniques, in the absence of a coating, with initially promising results in slowing intimal growth in coronary and peripheral arterial disease.[26,27] In an animal experiment, approximately 90% of the drug that was administered via this method was lost or delivered in the bloodstream.[27]
4) Leaky coils[28] were used in the Dispatch® catheter (Boston Scientific/SCIMED, Inc.; Fremont, Calif), but delivery was deemed inefficient, and this method was soon abandoned.
5) Needle-row balloons (Interventional Technologies, Inc.) (Fig. 3) featured triple metal rows of cone-shaped needles, each 0.25 mm in height. These balloons were studied in phase-2 clinical trials but did not attain clinical usage.[29]

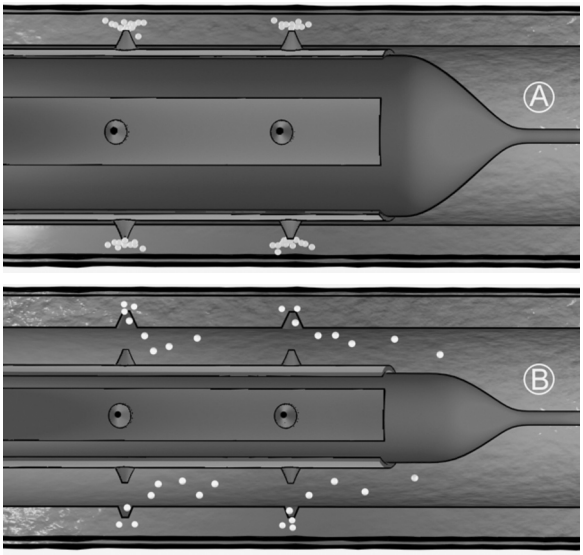

Fig. 3 *Computer-imaged rendition of the needle-row balloon, which enables deeper drug penetration into the vascular wall (**A**) but also allows drug leakage and washout after balloon deflation (**B**).*

Local Injection Devices

A novel concept in local drug delivery is a local injection device (LID), which incorporates retractable needles into a catheter device (Fig. 4).[30] Two competing LIDs have recently been developed—one by Bavaria Medizin Technologie GmbH (Oberpfaffenhofen, Germany)[30] and another by Binlab, Inc. (Webster, Tex). Both devices are patented, but neither is yet approved for clinical use. Each LID prototype consists of a catheter that has 3 or 4 specially designed retractable needles at its distal end. The proximal portion of the catheter houses a control mechanism that causes the needles to deploy and to penetrate the target coronary vascular layer to a predetermined depth—3 to 5 mm by the Binlab catheter, and up to 10 mm by the Bavaria catheter. In pigs, the Bavaria device has been successful in penetrating the adventitial layers[29] and, alternatively, the intimal layer[31] of coronary arteries. At present, the Binlab catheter has been tested only during preliminary, pilot studies in human cadavers and porcine coronary arteries (Fig. 5); its specially designed metal needles consistently entered the intima, stopped at the medial–intimal interface, and delivered the test solution. When injecting various volumes of the active drug solution over differing time periods, the operator was able to tailor the total quantities of the drug that were delivered at the target sites. The initial experience suggested that by changing the injected volume, the operator could vary the size of the circumferential, drug-filled reservoir (Figs. 5B and

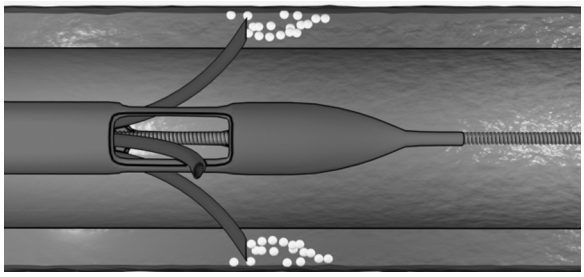

Fig. 4 *Computer-imaged rendition of the Binlab retractable-needle catheter (local injection device), which is designed to permit reliable, deep penetration and drug retention in the vascular wall.*



Fig. 1 *Computer-imaged rendition of selective administration of drugs in a coronary artery by means of a guiding catheter. Local retention of the drug is low and not site-specific.*



Fig. 2 *Computer-imaged rendition of the leaky-balloon technique, which results in low-efficiency drug delivery.*

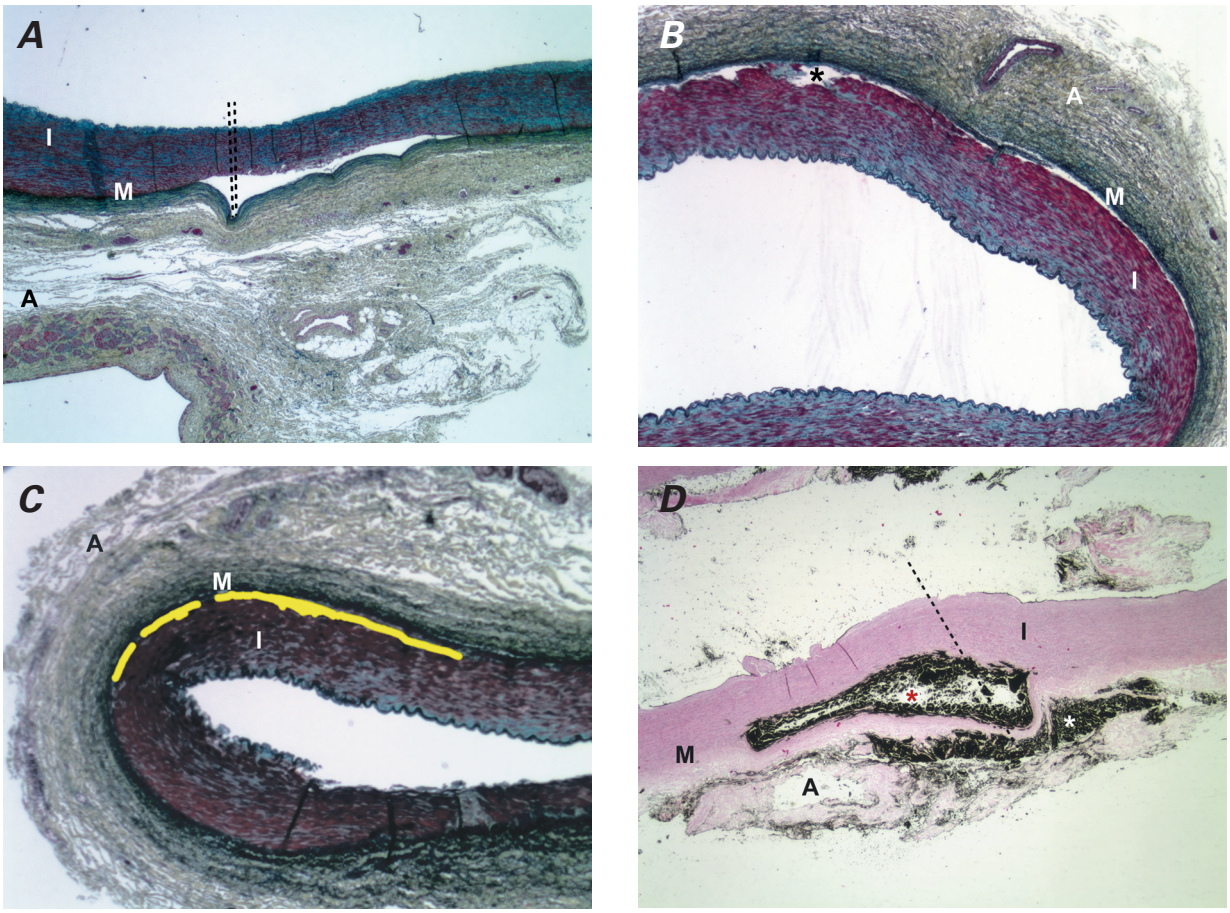

Fig. 5 *Photomicrograph shows histologic cross-sections of vessels that were treated with local injection devices in human cadaver specimens.* ***A****) Typical remnants of needle penetration, showing the deep imprints in the exact sites of penetration in the deformed media. The dashed line indicates the needle's trajectory. The white area between the intima (I) and the media (M) is the newly formed reservoir, where India ink was injected (and eventually washed out during histologic preparation by use of Movat's pentachrome stain). The adventitia (A) is also shown.* ***B****) The white area between the intima (I) and the media (M) is the newly formed reservoir (asterisk) inside the adventitial layer (A), where the injected solution typically accumulates circumferentially to varying extents, according to the volumes injected.* ***C****) The yellow-stained area shows the newly formed reservoir inside the adventitial layer (A) and (in yellow) between the intima (I) and the media (M).* ***D****) After penetration from the use of manual or mechanical force, the needle (trajectory, dotted line) enters new spaces that have been created in the media (red asterisk) and subadventitia (white asterisk). The needles are not long enough to progress beyond the adventitia into the pericardium. In these preparations, the injected India ink (shown in black) was preserved by use of hematoxylin & eosin stain.*

5C) just inside the internal elastic membrane, from which fibrocellular restenotic growth and migration originate.[1,4,5,32] After balloon predilation of the target lesion and the use of the LID as described, the general application of a BMS would be expected to complete the procedure. These initial observations suggested that fully circumferential impregnation of a 3- to 5-mm-diameter vascular wall could be achieved with adequate amounts of injected solution when 3 radially oriented needles are used.

Although further studies are needed, the LID approach promises to simply and efficiently solve many limitations of current DES. Chief among them are the following:

1) The excessive cost (especially when multiple vessels or lesions are involved).[33]
2) The otherwise complex and expensive approval process. Because the LID involves neither permanent implantation nor a life-threatening procedure, its developers could submit only a 510(k) premarket notification to the FDA for clearance of the LID—a much less onerous process of approval than the usual Investigational Device Exemptions (IDE) process.
3) The presence of a potentially thrombogenic stent-coating.
4) Potential toxic or hypersensitivity[34] effects of stent-coating on the intimal and endothelial cells, which could delay re-endothelialization (LIDs would be used jointly with BMSs).
5) Adaptable delivery of various quantities of different drug combinations, as suggested by the nature

of various local intimal substrates (for example, thrombotic vs calcific vs soft/fibrous vs lipid-laden plaques). The use of local injection devices could improve the efficiency and precision of local administration of the desired drug(s), as decided by the operator, according to protocols that still need to be developed. In this regard, it is relevant to emphasize that the lipophilic sirolimus molecule can easily cross the cell membrane and bind to cytosolic receptors intracellularly, enhancing chronic tissue retention.[35]

6) The dependence of DES on long-term antiplatelet inhibitors, which could still be insufficient in a substantial percentage of patients.[36]

In addition, LID technology might improve the results of even stand-alone balloon angioplasty for patients in whom stents are contraindicated (for example, in clopidogrel nonresponders or in patients who have superficial femoral artery lesions).

By enabling simple local administration of medical therapy or experimental biological substances, LIDs could also be used for the preliminary testing of new drugs and their combinations in animals or human beings, and for cellular or genetic therapy; such testing would be much more cost-effective than the testing of DES models. For instance, the Bavaria LID has been successfully used to establish an interesting experimental model of atherosclerotic plaques in pigs, by the administration of cholesteryl linoleate into the intima.[31]

The most relevant remaining question regarding the LID approach concerns the possibility of toxic effects if a drug is administered in "excessive doses" in procedures that could be difficult to standardize. In particular, the risk of delayed aneurysm formation or rupture could be a concern.[37]

Conclusions

In providing local drug delivery for vascular interventions, catheter-based retractable-needle devices may offer some unique benefits.[38] These devices could also presage novel, cost-effective interventions for the treatment of nonocclusive plaques that are considered vulnerable to rapid progression.[32,39] Eventually, LIDs might enable plaque stabilization (for example, in an unobstructed left main trunk or a venous graft lesion) by reducing the lipid burden or the inflammatory-cell population, or by locally administering direct antithrombin or tissue-factor inhibitors. These are only some of the possible investigational and therapeutic options that might be realized with these devices.

Acknowledgments

We acknowledge the editorial support of Virginia Fairchild for helping to prepare this article; of Hasitha Samarajeewa for providing the computer renditions of Figures 1 through 4; and of Tomas Klima, MD, for supplying the histologic preparations.

References

1. Popma JJ, Kurtz RE, Baim DS. Percutaneous coronary and valvular intervention. In: Zipes DP, Libby P, Bonow RO, Braunwald E, editors. Braunwald's heart disease: a textbook of cardiovascular medicine. 7th ed. Philadelphia: Elsevier Saunders; 2005. p. 1367-98.
2. Serruys PW, de Jaegere P, Kiemeneij F, Macaya C, Rutsch W, Heyndrickx G, et al. A comparison of balloon-expandable-stent implantation with balloon angioplasty in patients with coronary artery disease. Benestent Study Group. N Engl J Med 1994;331(8):489-95.
3. Fischman DL, Leon MB, Baim DS, Schatz RA, Savage MP, Penn I, et al. A randomized comparison of coronary-stent placement and balloon angioplasty in the treatment of coronary artery disease. Stent Restenosis Study Investigators. N Engl J Med 1994;331(8):496-501.
4. Kipshidze NN, Tsapenko MV, Leon MB, Stone GW, Moses JW. Update on drug-eluting coronary stents. Expert Rev Cardiovasc Ther 2005;3(5):953-68.
5. Drachman DE, Simon DI. Inflammation as a mechanism and therapeutic target for in-stent restenosis. Curr Atheroscler Rep 2005;7(1):44-9.
6. Sousa JE, Costa MA, Abizaid AC, Rensing BJ, Abizaid AS, Tanajura LF, et al. Sustained suppression of neointimal proliferation by sirolimus-eluting stents: one-year angiographic and intravascular ultrasound follow-up. Circulation 2001;104(17): 2007-11.
7. Morice MC, Serruys PW, Sousa JE, Fajadet J, Ban Hayashi E, Perin M, et al.; RAVEL Study Group. A randomized comparison of a sirolimus-eluting stent with a standard stent for coronary revascularization. N Engl J Med 2002;346(23): 1773-80.
8. Stone GW, Moses JW, Ellis SG, Schofer J, Dawkins KD, Morice MC, et al. Safety and efficacy of sirolimus- and paclitaxel-eluting coronary stents. N Engl J Med 2007;356(10): 998-1008.
9. Kastrati A, Mehilli J, Pache J, Kaiser C, Valgimigli M, Kelbaek H, et al. Analysis of 14 trials comparing sirolimus-eluting stents with bare-metal stents. N Engl J Med 2007;356(10):1030-9.
10. Ligthart S, Vlemmix F, Dendukuri N, Brophy JM. The cost-effectiveness of drug-eluting stents: a systematic review. CMAJ 2007;176(2):199-205.
11. Ong AT, Daemen J, van Hout BA, Lemos PA, Bosch JL, van Domburg RT, Serruys PW. Cost-effectiveness of the unrestricted use of sirolimus-eluting stents vs. bare metal stents at 1 and 2-year follow-up: results from the RESEARCH Registry. Eur Heart J 2006;27(24):2996-3003.
12. Colombo A, Chieffo A. Drug-eluting stent update 2007: part III: Technique and unapproved/unsettled indications (left main, bifurcations, chronic total occlusions, small vessels and long lesions, saphenous vein grafts, acute myocardial infarctions, and multivessel disease). Circulation 2007;116(12): 1424-32.
13. Coolong A, Kuntz RE. Understanding the drug-eluting stent trials. Am J Cardiol 2007;100(5A):17K-24K.
14. Steigen TK, Maeng M, Wiseth R, Erglis A, Kumsars I, Narbute I, et al.; Nordic PCI Study Group. Randomized study on simple versus complex stenting of coronary artery bifurcation lesions: the Nordic bifurcation study. Circulation 2006;114 (18):1955-61.

15. Moses JW, Leon MB, Popma JJ, Fitzgerald PJ, Holmes DR, O'Shaughnessy C, et al.; SIRIUS Investigators.. Sirolimus-eluting stents versus standard stents in patients with stenosis in a native coronary artery. N Engl J Med 2003;349(14):1315-23.
16. Stone GW, Ellis SG, Cannon L, Mann JT, Greenberg JD, Spriggs D, et al.; TAXUS V Investigators. Comparison of a polymer-based paclitaxel-eluting stent with a bare metal stent in patients with complex coronary artery disease: a randomized controlled trial. JAMA 2005;294(10):1215-23.
17. Camenzind E, Steg PG, Wijns W. Stent thrombosis late after implantation of first-generation drug-eluting stents: a cause for concern. Circulation 2007;115(11):1440-55.
18. Holmes DR Jr, Kereiakes DJ, Laskey WK, Colombo A, Ellis SG, Henry TD, et al. Thrombosis and drug-eluting stents: an objective appraisal. J Am Coll Cardiol 2007;50(2):109-18.
19. Luscher TF, Steffel J, Eberli FR, Joner M, Nakazawa G, Tanner FC, Virmani R. Drug-eluting stent and coronary thrombosis: biological mechanisms and clinical implications. Circulation 2007;115(8):1051-8.
20. Joner M, Finn AV, Farb A, Mont EK, Kolodgie FD, Ladich E, et al. Pathology of drug-eluting stents in humans: delayed healing and late thrombotic risk. J Am Coll Cardiol 2006;48 (1):193-202.
21. Otsuka Y, Chronos NA, Apkarian RP, Robinson KA. Scanning electron microscopic analysis of defects in polymer coatings of three commercially available stents: comparison of BiodivYsio, Taxus and Cypher stents. J Invasive Cardiol 2007; 19(2):71-6.
22. Camenzind E, De Scheerder IK, editors. Local drug delivery for coronary artery disease. London: Taylor & Francis; 2005. p. 1-213.
23. Touchard AG, Schwartz RS. Preclinical restenosis models: challenges and successes. Toxicol Pathol 2006;34(1):11-8.
24. Goldman B, Blanke H, Wolinsky H. Influence of pressure on permeability of normal and diseased muscular arteries to horseradish peroxidase. A new catheter approach. Atherosclerosis 1987;65(3):215-25.
25. Wilensky RL, March KL, Gradus-Pizlo I, Schauwecker D, Michaels MB, Robinson J, et al. Regional and arterial localization of radioactive microparticles after local delivery by unsupported or supported porous balloon catheters. Am Heart J 1995;129(5):852-9.
26. Scheller B, Speck U, Abramjuk C, Bernhardt U, Bohm M, Nickenig G. Paclitaxel balloon coating, a novel method for prevention and therapy of restenosis. Circulation 2004;110 (7): 810-4.
27. Scheller B, Hehrlein C, Bocksch W, Rutsch W, Haghi D, Dietz U, et al. Treatment of coronary in-stent restenosis with a paclitaxel-coated balloon catheter. N Engl J Med 2006;355 (20):2113-24.
28. Mitchel JF, Fram DB, Palme DF 2nd, Foster R, Hirst JA, Azrin MA, et al. Enhanced intracoronary thrombolysis with urokinase using a novel, local drug delivery system. In vitro, in vivo, and clinical studies. Circulation 1995;91(3):785-93.
29. Barath P, Popov A, Dillehay GL, Matos G, McKiernan T. Infiltrator angioplasty balloon catheter: a device for combined angioplasty and intramural site-specific treatment. Cathet Cardiovasc Diagn 1997;41(3):333-41.
30. Gonschior P, Backfisch G, Muth G, Schiele R, Vogel-Wiens C, Pahl C, Sponer G. Local drug delivery via transvascular injection. J Invasive Cardiol 1999;11(10):600-7.
31. Granada JF, Moreno PR, Burke AP, Schulz DG, Raizner AE, Kaluza GL. Endovascular needle injection of cholesteryl linoleate into the arterial wall produces complex vascular lesions identifiable by intravascular ultrasound: early development in a porcine model of vulnerable plaque. Coron Artery Dis 2005; 16(4):217-24.
32. Fuster V. Lewis A. Conner Memorial Lecture. Mechanisms leading to myocardial infarction: insights from studies of vascular biology [published erratum appears in Circulation 1995; 91(1):256]. Circulation 1994;90(4):2126-46.
33. Kong DF, Eisenstein EL, Sketch MH Jr, Zidar JP, Ryan TJ, Harrington RA, et al. Economic impact of drug-eluting stents on hospital systems: a disease-state model. Am Heart J 2004;147(3):449-56.
34. Nebeker JR, Virmani R, Bennett CL, Hoffman JM, Samore MH, Alvarez J, et al. Hypersensitivity cases associated with drug-eluting coronary stents: a review of available cases from the Research on Adverse Drug Events and Reports (RADAR) project. J Am Coll Cardiol 2006;47(1):175-81.
35. Levin AD, Vukmirovic N, Hwang CW, Edelman ER. Specific binding to intracellular proteins determines arterial transport properties for rapamycin and paclitaxel. Proc Natl Acad Sci USA 2004;101(25):9463-7.
36. Eisenstein EL, Anstrom KJ, Kong DF, Shaw LK, Tuttle RH, Mark DB, et al. Clopidogrel use and long-term clinical outcomes after drug-eluting stent implantation. JAMA 2007;297 (2):159-68.
37. Popma JJ, Leon MB, Moses JW, Holmes DR Jr, Cox N, Fitzpatrick M, et al.; SIRIUS Investigators. Quantitative assessment of angiographic restenosis after sirolimus-eluting stent implantation in native coronary arteries. Circulation 2004; 110(25):3773-80.
38. Shah PK, Yano J, Reyes O, Chyu KY, Kaul S, Bisgaier CL, et al. High-dose recombinant apolipoprotein A-I(milano) mobilizes tissue cholesterol and rapidly reduces plaque lipid and macrophage content in apolipoprotein e-deficient mice. Potential implications for acute plaque stabilization. Circulation 2001;103(25):3047-50.
39. Serruys PW, Garcia-Garcia HM, Regar E. From postmortem characterization to the in vivo detection of thin-capped fibroatheromas: the missing link toward percutaneous treatment: what if Diogenes would have found what he was looking for? J Am Coll Cardiol 2007;50(10):950-2.