Intrapericardial Primary Thymic Carcinoma in a 73-Year-Old Man

Ana Maria Calderon, MD
Juan Andres Merchan, MD
Juan Carlos Rozo, MD
Cesar Ivan Guerrero, MD
Bernardo Treistman, MD
Laura E. Sulak, MD
Benjamin Y.C. Cheong, MD
German Rodríguez, MD
Andrés Mesa, MD

Thymic carcinoma is a rare, highly aggressive type of tumor that typically occurs in the anterior mediastinum. We describe the case of a 73-year-old man who presented with weakness, cough, dyspnea, anorexia, and weight loss. An echocardiogram showed an intrapericardial mass that occupied the space around the lateral walls of the left ventricle and distally compressed the right ventricle. Magnetic resonance imaging and a biopsy confirmed the presence of intrapericardial primary thymic carcinoma. The patient underwent surgical excision of the tumor and died of right ventricular rupture during the procedure. This case highlights the importance of considering thymic carcinoma whenever an otherwise unexplained intrapericardial mass is encountered. ***(Tex Heart Inst J 2008;35 (4):458-61)***

Thymic carcinoma is a rare, aggressive, epithelial malignant tumor that usually occurs in the anterior mediastinum. The typical patient is a 30- to 50-year-old man. Thymic carcinomas that involve the heart tend to be metastasized mediastinal tumors and seldom originate intrapericardially. It is possible that during the embryologic stage some thymic tissue is left behind in the pericardium as the thymus develops. Such tissue may turn into an intrapericardial tumor.[1] Only a few primary intrapericardial thymic carcinomas have been reported in the medical literature.[2-6] We recently encountered such a lesion in an elderly patient.

Case Report

A 73-year-old man presented at his local emergency department because of weakness, an intermittent nonproductive cough, dyspnea, and anorexia that had led to an 8-pound weight loss during the previous 3 weeks. Chest radiography revealed a markedly enlarged cardiac silhouette. Echocardiography showed a thick layer of heterogeneous echogenic material that occupied the pericardial space around the lateral walls of the left ventricle. The right ventricle was distally compressed; however, all the cardiac chambers were of normal size. Small right-sided and posterior pericardial effusions were present, as was evidence of a large pericardial mass (Fig. 1).

The patient was transferred to our hospital for cardiologic evaluation and further treatment. On physical examination, he was in mild respiratory distress, with a blood pressure of 110/80 mmHg, a pulse of 90 beats/min, a respiratory rate of 22 breaths/min, and jugular venous pressure of 8 mmHg. On auscultation, the chest was clear and the heart sounds were diminished, without murmurs or friction. Other physical findings were normal.

Magnetic resonance imaging (Fig. 2) and magnetic resonance angiography (Fig. 3) showed a heterogeneous mass in the pericardial space. The mass encased most of the heart, extending to the level of the main pulmonary artery and the distal ascending aorta. No myocardial involvement was apparent, and cardiac function was not compromised. To alleviate the patient's respiratory symptoms, surgical excision of the tumor was performed through a median sternotomy. However, the tumor resection was complicated by a right ventricular rupture, and the patient died on the operating table.

Histopathologic examination of the specimen showed a thymic carcinoma characterized by large, highly pleomorphic, undifferentiated cells, occasional bizarre cells, and a high mitotic rate, with zones of necrosis (Fig. 4). Most of the cells displayed eosinophilic nucleoli.

Key words: *Intrapericardial tumors; pericardium/pathology; thymus neoplasms/pathology; thymic carcinoma/diagnosis/echocardiography/magnetic resonance imaging/surgery*

From: *Department of Cardiology (Drs. Calderon, Cheong, Guerrero, Merchan, Mesa, Rodríguez, Rozo, Sulak, and Treistman), Texas Heart Institute at St. Luke's Episcopal Hospital, Houston, Texas 77030; and Corbic Research Foundation-HMUA (Dr. Mesa), Envigado, Colombia*

Address for reprints: *Andrés Mesa, MD, 6624 Fannin, Suite 2390, Houston, TX 77030*

E-mail: amesa@comcast.net

© 2008 by the Texas Heart® Institute, Houston

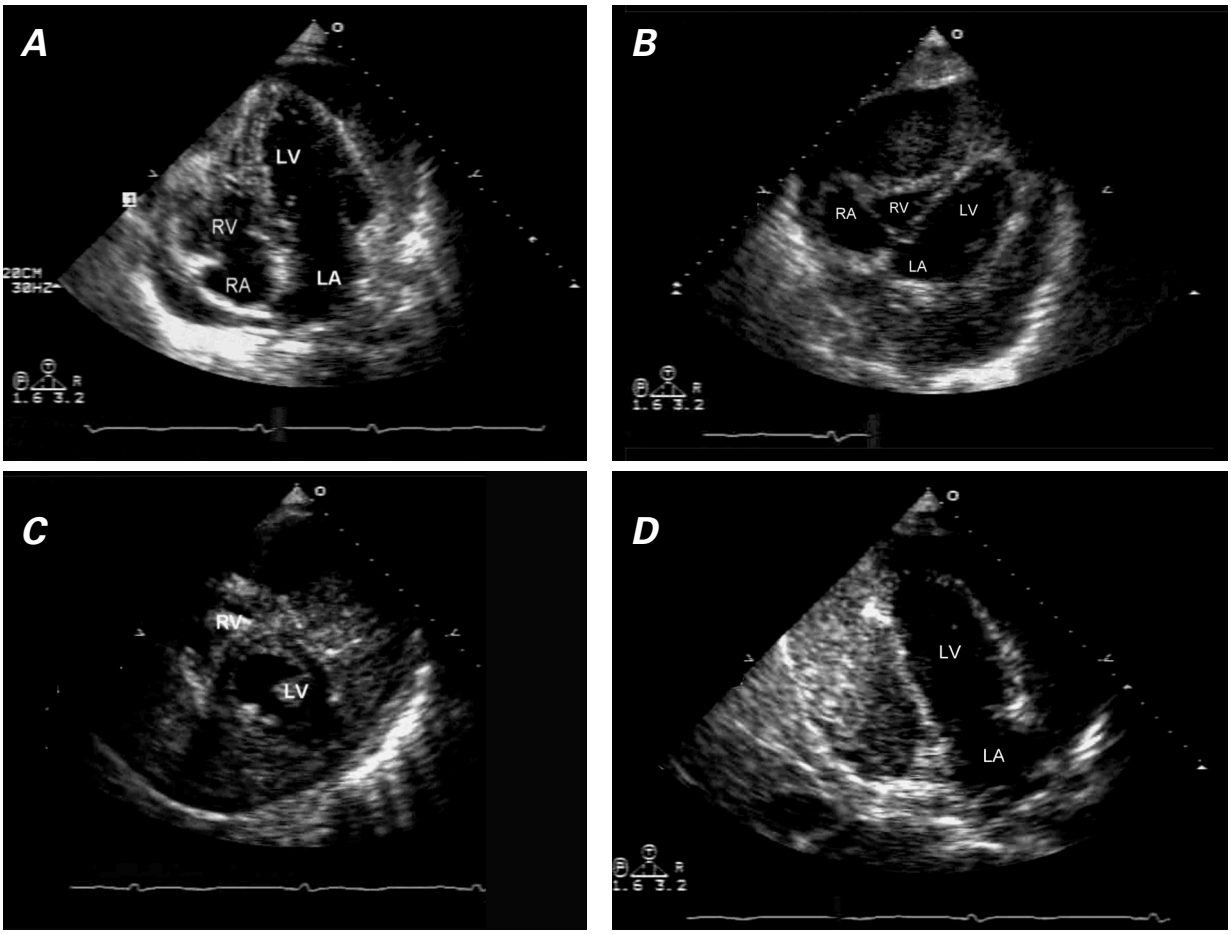

Fig. 1 *Echocardiography.* ***A****) Apical 4-chamber view shows a thick layer of heterogeneous echogenic material occupying the pericardial space around the lateral walls of the left ventricle and apex and around the right ventricular free wall.* ***B****) Subcostal view shows that all 4 chambers are normal in size and thickness, the right ventricle is compressed distally, and there is a small right-sided and posterior pericardial effusion behind the right atrium.* ***C****) Parasternal short-axis view shows a complex heterogenic structure surrounding both ventricles.* ***D****) Apical 2-chamber view shows evidence of a mass in the pericardium (to the left of the 2 chambers and the inferior wall).*

LA = left atrium; LV = left ventricle; RA = right atrium; RV = right ventricle

Real-time motion images are available at texasheart.org/journal.

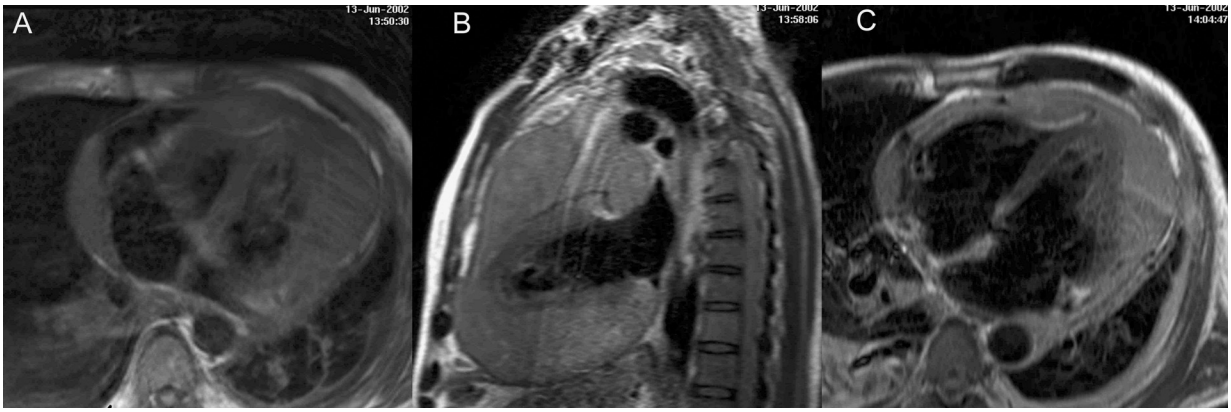

Fig. 2 *Magnetic resonance images.* ***A****) T_1-weighted spin echo image shows an intrapericardial mass (with low-to-intermediate signal intensity) adjacent to the left ventricle, right ventricle, and right atrium.* ***B****) T_2-weighted spin echo sagittal image, in the 2-chamber orientation, shows the intrapericardial mass (with low-to-intermediate signal intensity) surrounding the entire left ventricle and extending cranially.* ***C****) T_2-weighted spin echo image, in the 4-chamber orientation, shows the intrapericardial mass (with low-to-intermediate signal intensity) adjacent to the left and right ventricles.*

Fig. 3 *Gadolinium-enhanced magnetic resonance angiogram of the great vessels in the coronal projection.* ***A****) Arterial image. In the* ***B****) venous and* ***C****) delayed images, an increased uptake of contrast material by the pericardial mass is seen, suggesting a possible neoplastic process.*

Discussion

Thymic carcinoma is an aggressive, invasive epithelial malignancy that has many histologic subtypes. This uncommon tumor occasionally affects the heart, usually as a metastatic mediastinal tumor. Very rarely, however, thymic carcinoma originates intrapericardially,[1-6] as it did in this patient. Because the pericardium has limited space for growth, some of the 1st clinical indications of intrapericardial thymic tumors stem from mechanical compression or pericardial effusion.[4,7] Symptoms include chest pain, cough, or dyspnea, and can include anorexia, weight loss, and symptoms typically associated with superior vena cava syndrome and cardiac tamponade.[8] On occasion, patients who have thymic carcinoma may be completely asymptomatic. As in this patient, thymic carcinomas usually compress the great vessels and invade the lungs, regional lymph nodes, mediastinal fat, pericardium, or pleura. Unlike benign thymomas, thymic carcinomas are seldom associated with myasthenia gravis.

Computed tomography of thymic carcinoma shows a homogeneous or heterogeneous mass with lobulated or irregular contours. Other common findings include necrosis, hemorrhage, calcification, or cyst formation. Lung nodules—suggesting metastases, diaphragmatic elevation due to phrenic nerve palsy, and hilar lymph node enlargement—can also herald thymic carcinoma. Magnetic resonance images of this entity show an intermediate or high signal intensity on T_1- and T_2-weighted images, respectively. Fluorine-18 fluorodeoxyglucose positron emission tomography can distinguish thymic carcinoma from other, similar conditions. A high standardized uptake value of 5.0 may differentiate thymic carcinoma from thymoma, thymic hyperplasia, and a normal thymus. This cutoff value has a sensitivity of 84.6%, a specificity of 92.3%, and an accuracy of 88.5%.[9,10] In cases of primary thymic carcinoma, immunohistochemical expression of the marker KIT (CD117) is a diagnostic clue.

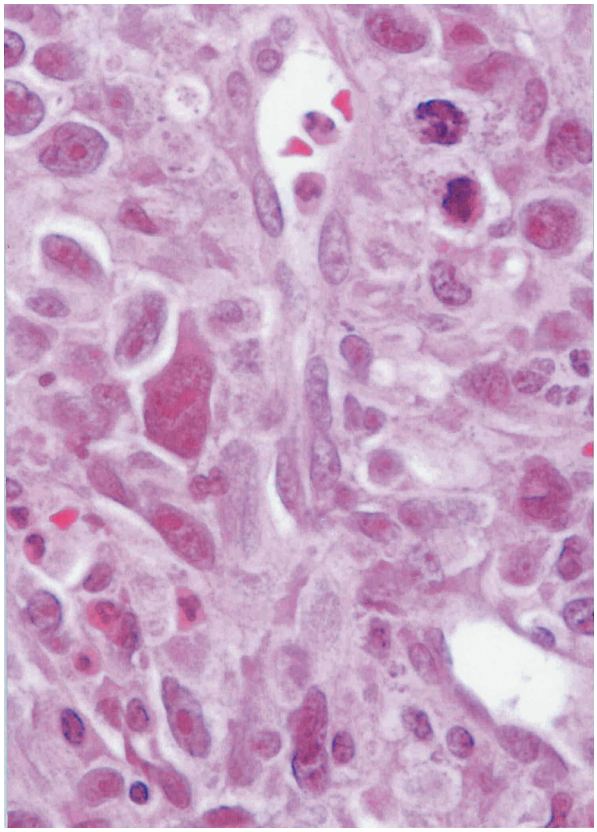

Fig. 4 *Microscopic appearance of the tumor, which exhibits highly pleomorphic, undifferentiated large cells, occasional bizarre tumor cells, and a high mitotic rate, with zones of necrosis. Most of the tumor cells display eosinophilic nucleoli. The combined histologic and immunohistochemical features are those of a high-grade malignant epithelial neoplasm. These findings are consistent with a diagnosis of thymic carcinoma (H & E, orig. ×400).*

The prognosis and treatment of thymic carcinoma depend on the cancer stage and grade. The Masaoka

staging system,[11] which is used to evaluate thymomas, is not useful for the assessment of thymic carcinoma. Indications of a poor prognosis include infiltration of the tumor margin, high-grade atypia and necrosis, mitoses, and absence of a lobular growth pattern. The most effective treatment is complete surgical resection. Nonaka and associates[12] evaluated 25 patients with proven thymic carcinoma: 6 underwent complete surgical resection, 1 underwent incomplete resection followed by chemoradiotherapy, 6 were treated with radiotherapy alone, 3 with radiotherapy plus chemotherapy, and 9 with chemotherapy alone as the initial treatment. The authors advocated complete resection, and found that patients treated with radiotherapy had better survival rates and less recurrence than nonirradiated patients.

In conclusion, our patient was a 73-year-old man who had an unusual intrapericardial tumor. Echocardiography, magnetic resonance imaging, and a biopsy confirmed that the tumor was a primary thymic carcinoma. Although quite rare, this type of tumor should be considered whenever an otherwise unexplained intrapericardial mass is encountered.

References

1. McAllister HA, Fenoglio JJ. Tumors of the cardiovascular system. Fascicle 15, 2nd Series: In: Atlas of tumor pathology. Washington, DC: Armed Forces Institute of Pathology; 1978.
2. Mirra M, Zanella M, Bussani R, Falconieri G. Intrapericardial thymoma: report of two incidental autopsy cases and review of the literature. Arch Pathol Lab Med 1997;121(1):59-63.
3. Burke A, Virmani R. Tumors of the heart and great vessels. Fascicle 16, 3rd Series: In: Atlas of tumor pathology. Washington, DC: Armed Forces Institute of Pathology; 1996.
4. Blaker H, Dragoje S, Laissue JA, Otto HF. Pericardial involvement by thymomas. Entirely intrapericardial thymoma and a pericardial metastasis of thymoma with glomeruloid vascular proliferations. Pathol Oncol Res 1999;5(2):160-3.
5. Turkmen N, Eren B, Comunoglu N, Fedakar R, Senel B. Pericardial thymoma: an unusual cause of sudden death. Ann Acad Med Singapore 2008;37(3):253-4.
6. Eglen DE. Pericardial based thymoma: diagnosis by fine needle aspiration. Indiana Med 1986;79(6):526-8.
7. Gupta K, Mathur VS. Diagnosis of pericardial disease using percutaneous biopsy: case report and literature review. Tex Heart Inst J 2003;30(2):130-3.
8. Detterbeck FC, Parsons AM. Thymic tumors. Ann Thorac Surg 2004;77(5):1860-9.
9. Ferdinand B, Gupta P, Kramer EL. Spectrum of thymic uptake at 18F-FDG PET. Radiographics 2004;24(6):1611-6.
10. Sasaki M, Kuwabara Y, Ichiya Y, Akashi Y, Yoshida T, Nakagawa M, et al. Differential diagnosis of thymic tumors using a combination of 11C-methionine PET and FDG PET. J Nucl Med 1999;40(10):1595-601.
11. Lardinois D, Rechsteiner R, Lang RH, Gugger M, Betticher D, von Briel C, et al. Prognostic relevance of Masaoka and Muller-Hermelink classification in patients with thymic tumors. Ann Thorac Surg 2000;69(5):1550-5.
12. Nonaka T, Tamaki Y, Higuchi K, Katoh H, Nakahashi M, Horikoshi H, et al. The role of radiotherapy for thymic carcinoma. Jpn J Clin Oncol 2004;34(12):722-6.